

23<sup>rd</sup>

INTERNATIONAL  
ULTMANN  
CHICAGO  
LYMPHOMA  
SYMPOSIUM

APRIL 10-11, 2026

JW MARRIOTT CHICAGO  
#IUCLS2026



*This activity is jointly provided by:*



23<sup>rd</sup>

INTERNATIONAL  
ULTMANN  
CHICAGO  
LYMPHOMA

# Case 2: Advanced Stage HL in an older patient with RA

---

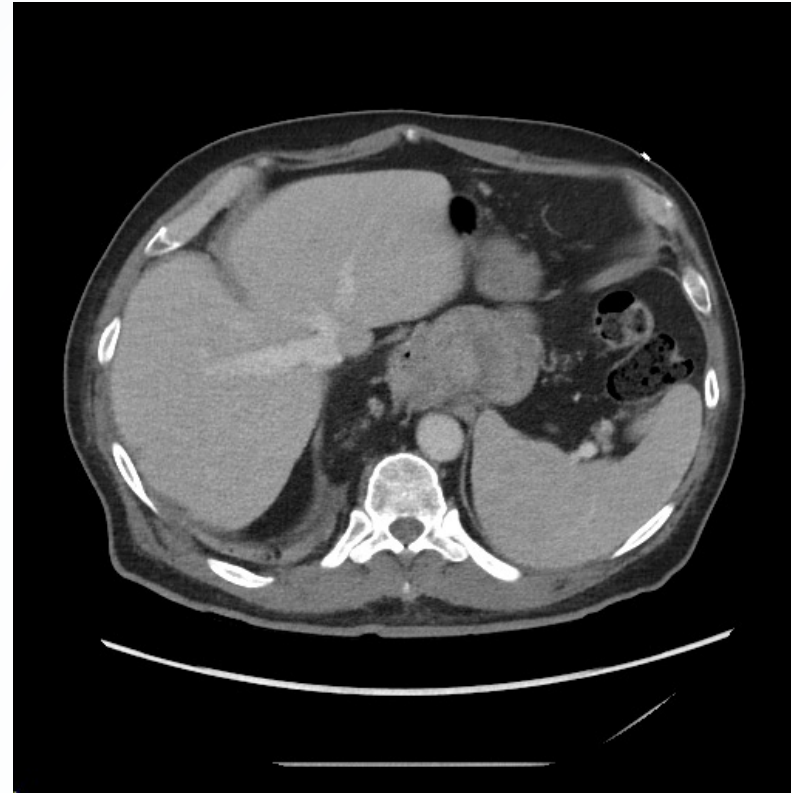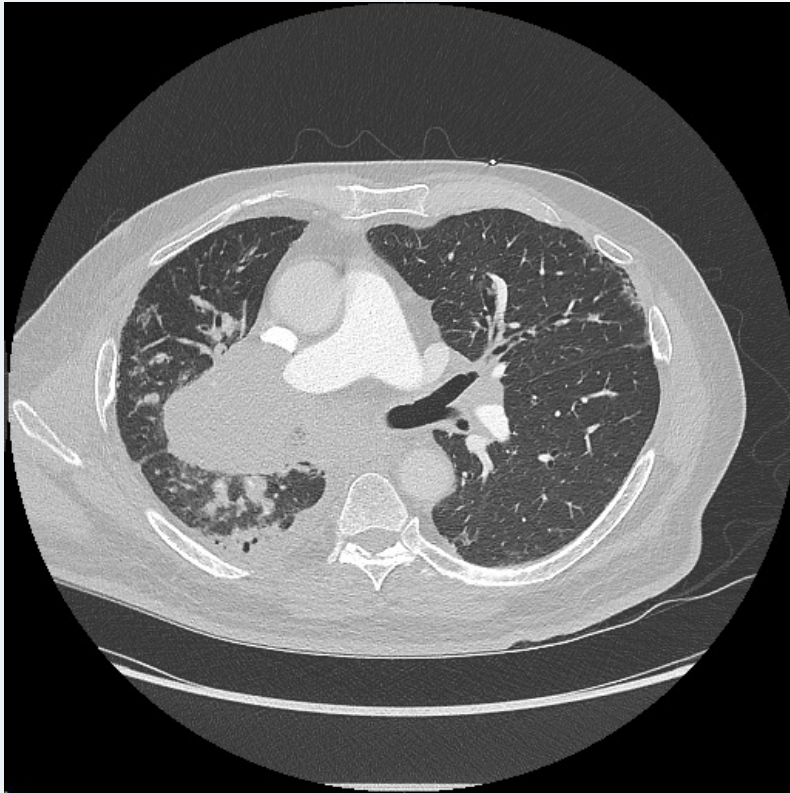
Reid Shaw, MD  
Hematology/Oncology Fellow  
University of Chicago

# Disclosures

Unfortunately, none.

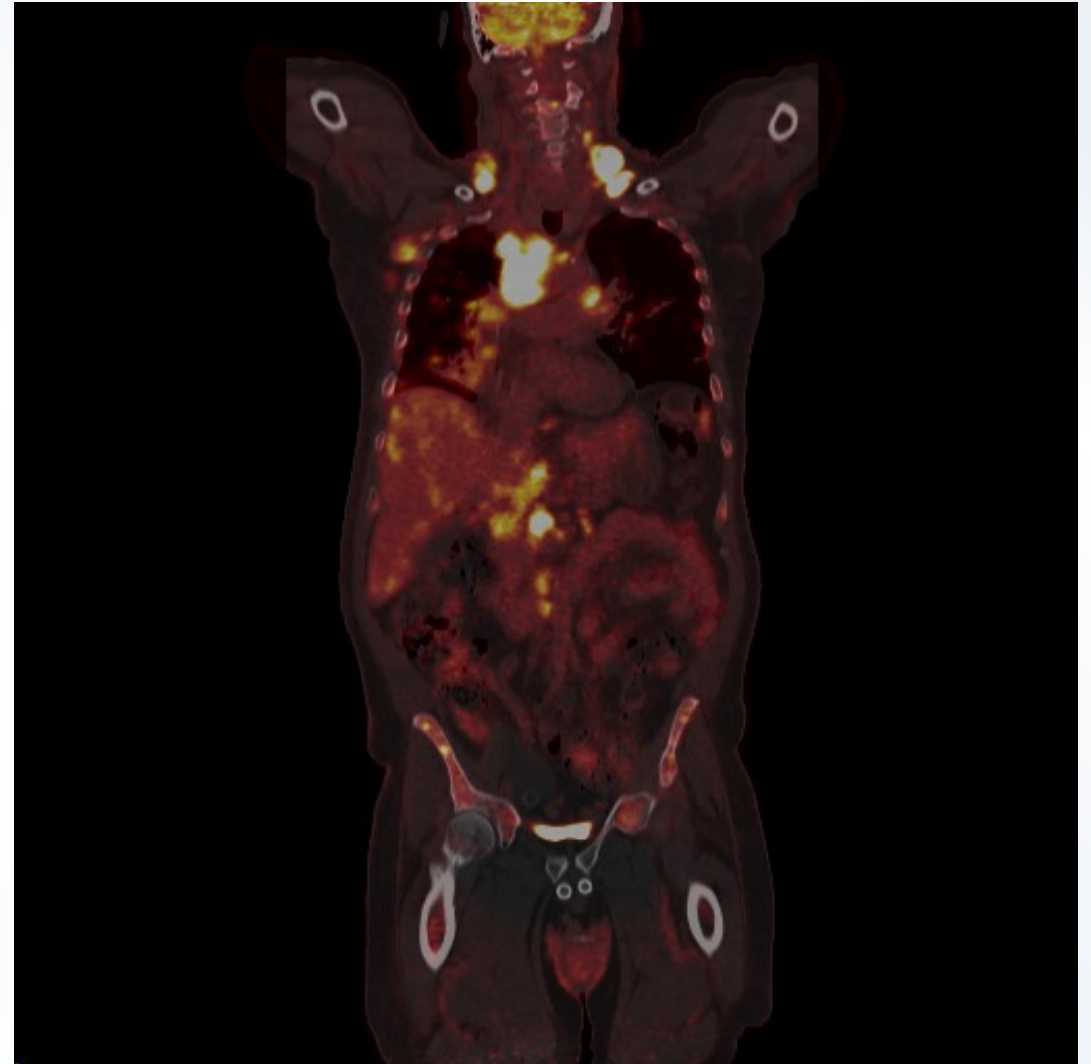
# 66 yo M with a h/o rheumatoid arthritis on MTX p/w 50 lb unintentional weight loss, SOB, CP, and cough

- Acute PE and post-obstructive PNA
- Diffuse LAD



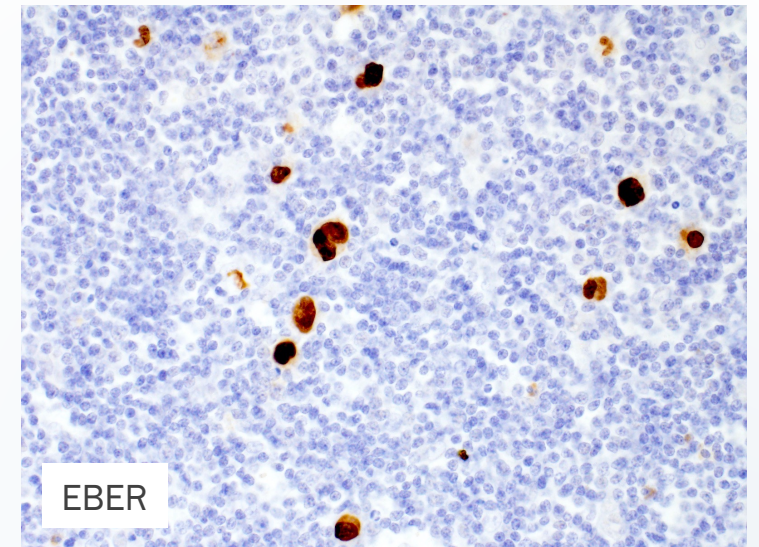
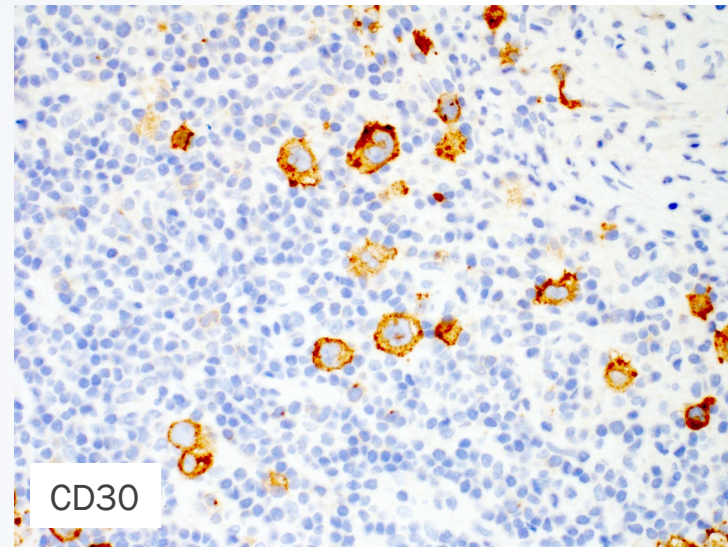
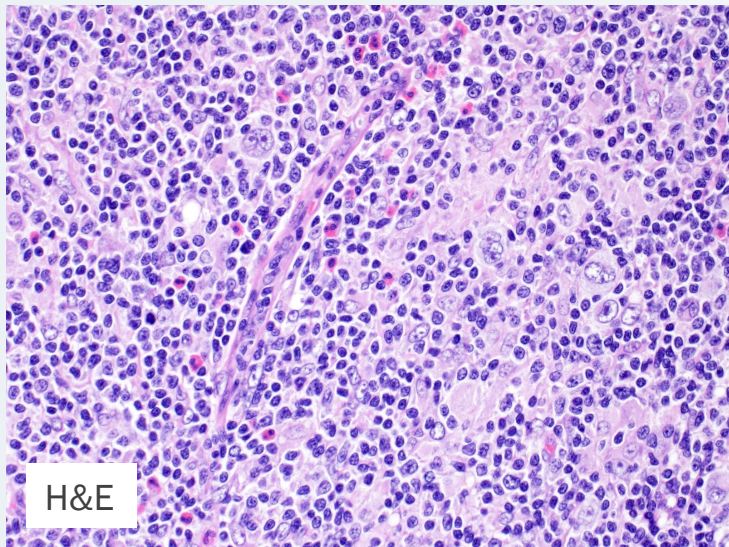
## Initial work-up

- CBC was normal
- ESR elevated to 120
- Albumin of 3
- LDH was normal
- TTE with normal LVEF
- PFTs with mild restrictive pattern

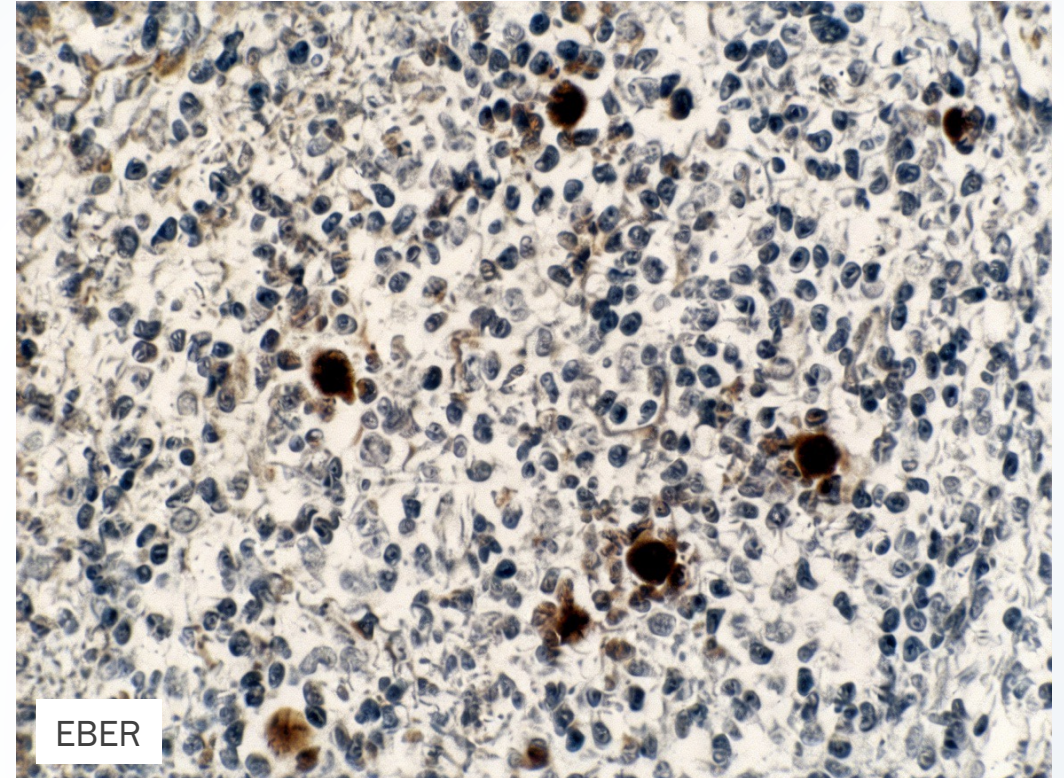
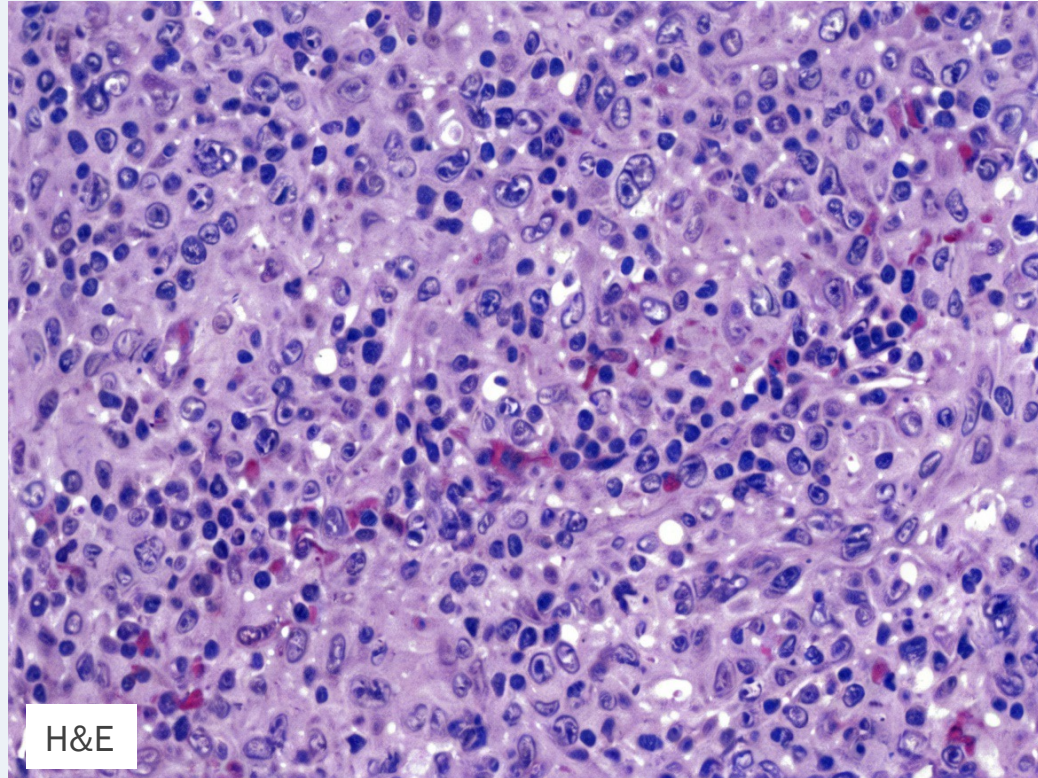


# FNA of mediastinal mass c/w cHL

- Scattered mononuclear variants of Hodgkin cells in a background rich in histiocytes
- CD30+, PAX5 (weak), EBER+, CD20- , CD15-



# Could this patient's RA or immunosuppression contributed to lymphoma development?



WHO 2017.

# How would you approach treatment in this patient?

- Nivolumab-AVD<sup>1</sup>
- BV followed by AVD then consolidative BV<sup>2</sup>
- BV + dacarbazine<sup>3</sup>
- BV + nivolumab<sup>4</sup>
- PVAB<sup>5</sup>

1) Rutherford et al., JCO 2025; 2) Evans et al., JCO 2018. 3) Friedberg et al., Blood 2017. 4) Friedberg et al., Blood 2024. 5) Ghesquieres et al., Blood 2024.

# Multidisciplinary conference recommended nivo-AVD

- 7/2025: Diagnosed with advanced-stage HL, held MTX
- 8/2025: C1 nivo-AVD
- 9/2025: Passed away in his sleep

23<sup>rd</sup>

INTERNATIONAL  
ULTMANN  
CHICAGO  
LYMPHOMA  
SYMPOSIUM

APRIL 10-11, 2026

JW MARRIOTT CHICAGO  
#IUCLS2026



*This activity is jointly provided by:*

