

23rd

INTERNATIONAL
ULTMANN
CHICAGO
LYMPHOMA
SYMPOSIUM

APRIL 10-11, 2026

JW MARRIOTT CHICAGO
#IUCLS2026



This activity is jointly provided by:



23rd

INTERNATIONAL
ULTMANN
CHICAGO
LYMPHOMA

Case 3: Relapsed/Refractory Hodgkin Lymphoma

Alexandra Rojek, MD
Instructor and Elwood V. Jensen Scholar
University of Chicago

Disclosures

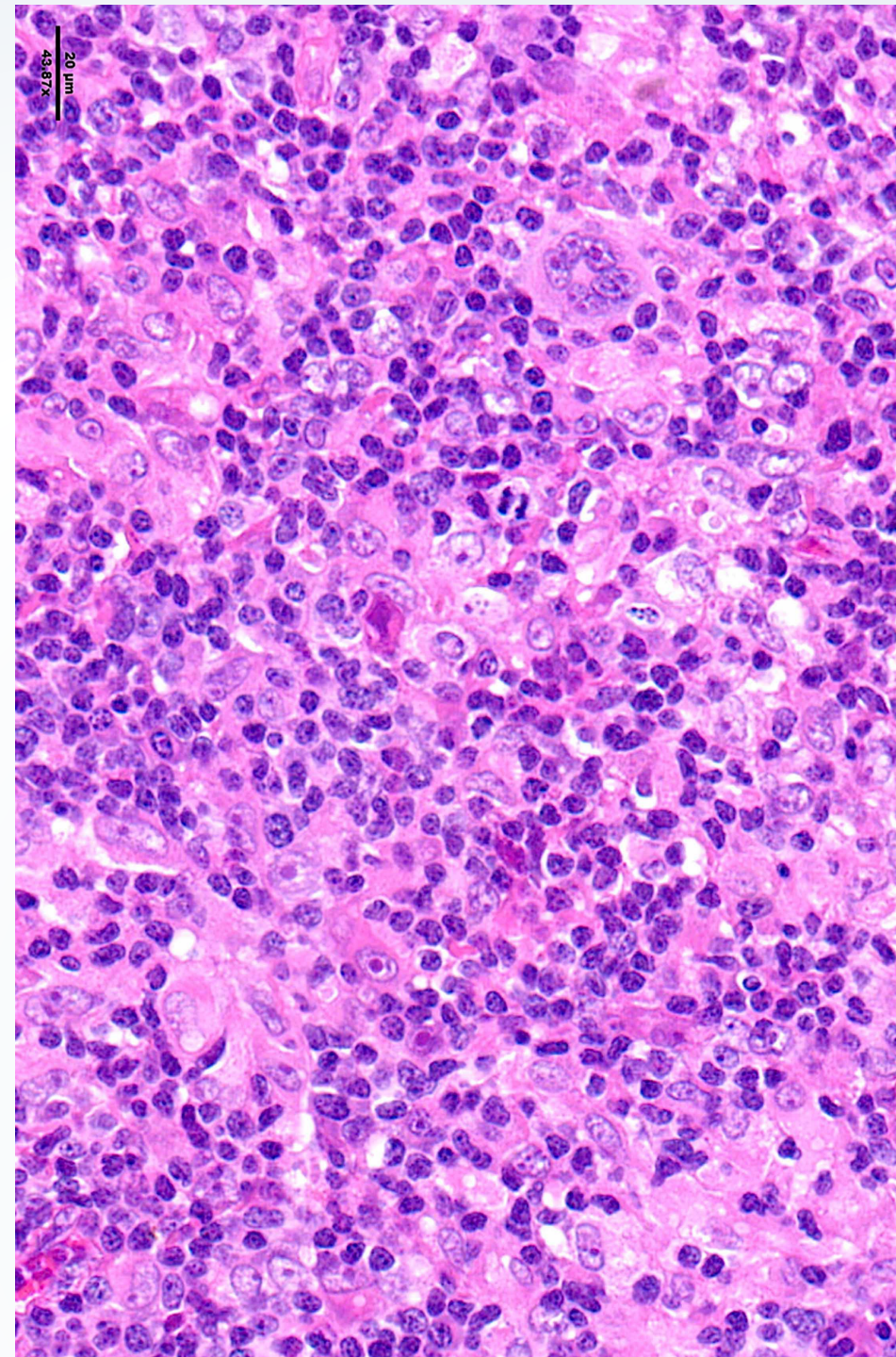
A.E.R reports the following financial disclosures:

- Advisory board: Incyte
- Consulting: Deciphera Pharmaceuticals

Case 3: R/R Hodgkin Lymphoma

49yo woman with history of advanced-stage Hodgkin lymphoma initially treated with ABVD x6 cycles now presenting with multiply relapsed disease.

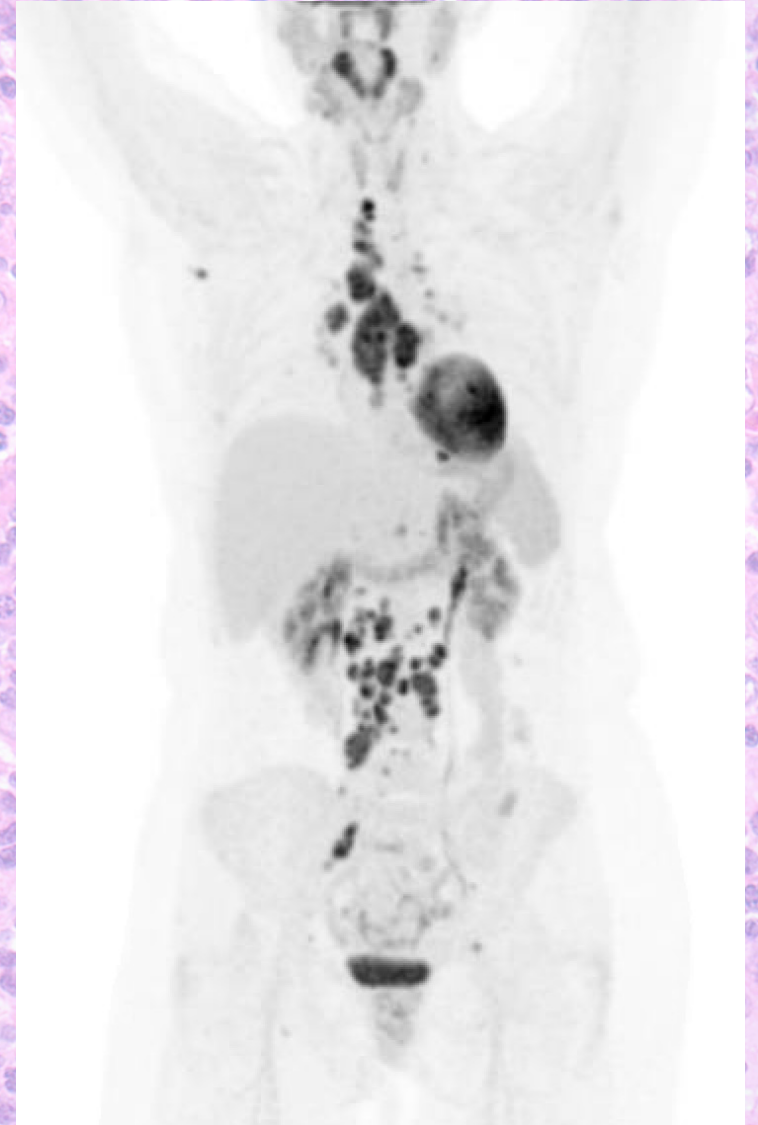
- In 2014 (age 38) presented with stage III disease, biopsy showing mixed cellularity HL, treated with 6 cycles of **ABVD**, with EOT PET/CT c/w CR
- 6 months later, presented with c/f disease recurrence on imaging
 - Biopsy proven recurrence in supraclavicular LN
 - Started **ICE** salvage chemotherapy x 3 cycles → CR vs very good PR → **autoSCT with BEAM conditioning**
 - Did not receive BV consolidation



Case 3: R/R Hodgkin Lymphoma

49yo woman with history of limited-stage Hodgkin lymphoma initially treated with ABVD x6 cycles now presenting with multiply relapsed disease.

- post-autoSCT with low-level SUV uptake in several LNs but given that size < 1cm, started on observation
- Do you consider treatment vs further observation? What are the threshold for starting treatment?



Case 3: R/R Hodgkin Lymphoma

49yo woman with history of limited-stage Hodgkin lymphoma initially treated with ABVD x6 cycles now presenting with multiply relapsed disease.

- In 2018, increase in number, size, and FDG-uptake of LNs on surveillance PET c/f disease relapse
 - Did not undergo biopsy at this time
 - Started on **BV** monotherapy → short response of several months
- Late 2018, again with progressive disease → started on **pembrolizumab** monotherapy
- Achieved a good partial response which lasted until early 2021 (2+ years) with progression noted only on imaging, remains asymptomatic at time of progression

- She presents to discuss next-line treatment options: what would you recommend?

R/R Hodgkin lymphoma treatment options

- 2+ prior lines of therapy including prior autoSCT
 - **Goal: achieve CR → alloSCT consolidation**
- Treatment options for alloSCT candidate:
 - BV-Nivo
 - CPI/BV +/- chemotherapy
 - Pembro-GVD
 - Pembro-ICE
 - Nivo-ICE
 - DHAP
 - ISRT
- Non-alloSCT candidate:
 - CPI monotherapy
 - BV monotherapy
 - ISRT
 - Gemcitabine
 - Bendamustine
- irrespective of candidacy for alloSCT:
 - **Clinical trials**
 - Other cellular therapies emerging?

Case 3, continued:

49yo woman with history of limited-stage Hodgkin lymphoma initially treated with ABVD x6 cycles now presenting with multiply relapsed disease.

- alloSCT discussion – pt has some reservations re: GVHD risk, donor options, etc
- In 2021, started **bendamustine** monotherapy
 - PET/CT after 3 cycles: CR
 - PET/CT after 6 cycles: PD, remains asymptomatic
- Late 2022: starts retreatment with **pembrolizumab**
 - Short-lived response for 3 months
- Next lines of therapy:
 - Clinical trial of **ipilimumab** → progression
 - **Ipi/nivo** → continued on **nivo** monotherapy after some response
 - Developed slow, asymptomatic progression

Case 3, continued:

49yo woman with history of limited-stage Hodgkin lymphoma initially treated with ABVD x6 cycles now presenting with multiply relapsed disease.

- Now with continued progression in 2025 (11 yrs from initial diagnosis)
 - Recommended clinical trial option: **ASTX-727 + nivolumab**
 - Achieved stable disease
 - Repeat discussion of **alloSCT**
 - MUD donor identified
 - 3 cycles of GND salvage chemotherapy --> near CR
 - Flu/Cy/TBI 200 conditioning with PTCy
 - **D30 PET: Deauville 3**
 - **D100 PET: Deauville 1**, continues in CR to present
 - Complicated by skin and upper GI aGVHD