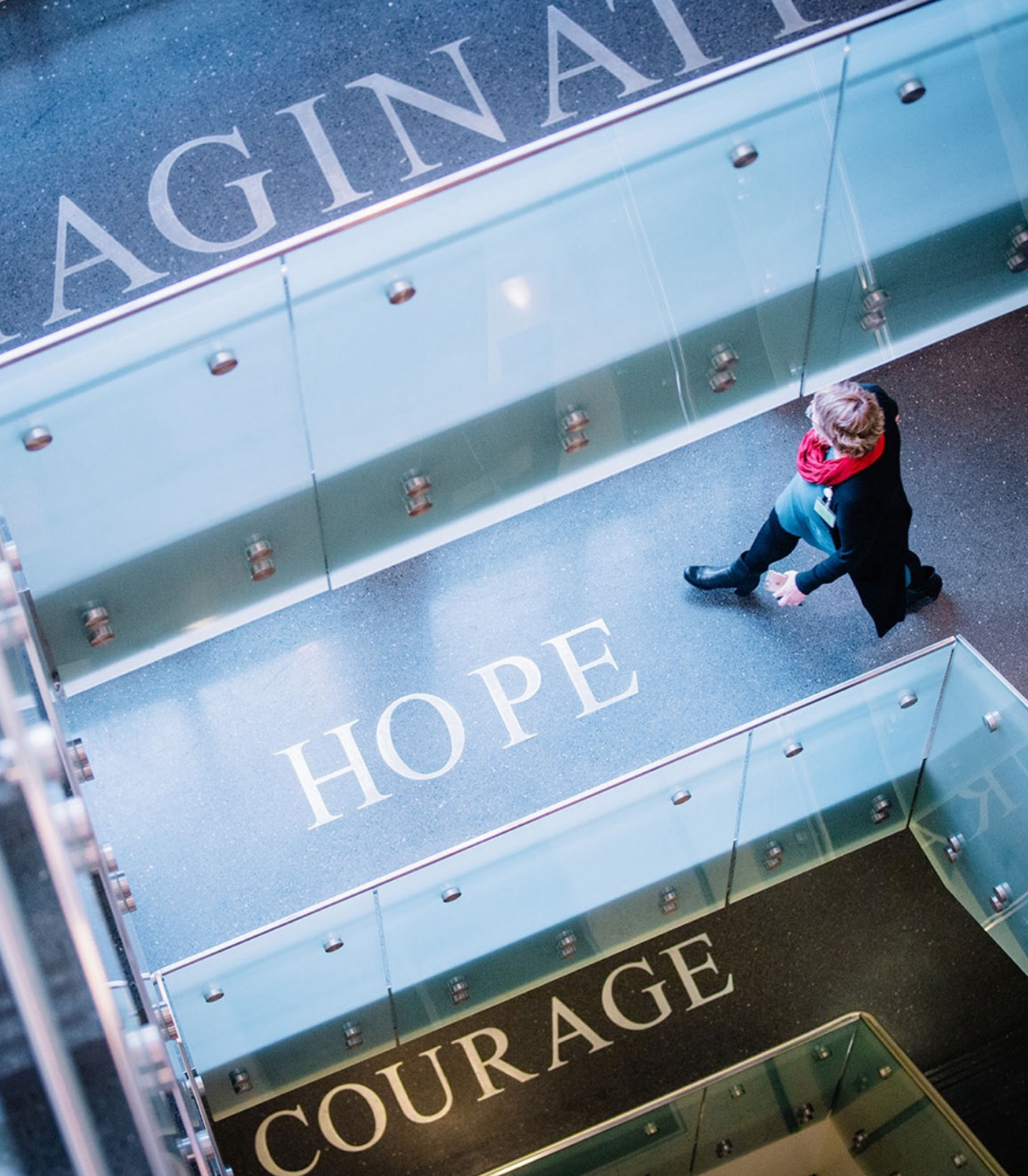



# Where Science Becomes Hope

## Patient-Based Panel Discussion Gynecological Malignancies

- All Speakers: Drs. Scalici, Modesitt, Manning-Geist,
- Case presented by Emory University Hematology-  
Oncology fellow: Mosun Oyenuga MD MPH

July 26, 2025



**EMORY**  
**WINSHIP**  
**CANCER**  
**INSTITUTE**  
National Cancer Institute-Designated  
Comprehensive Cancer Center

**NCI**

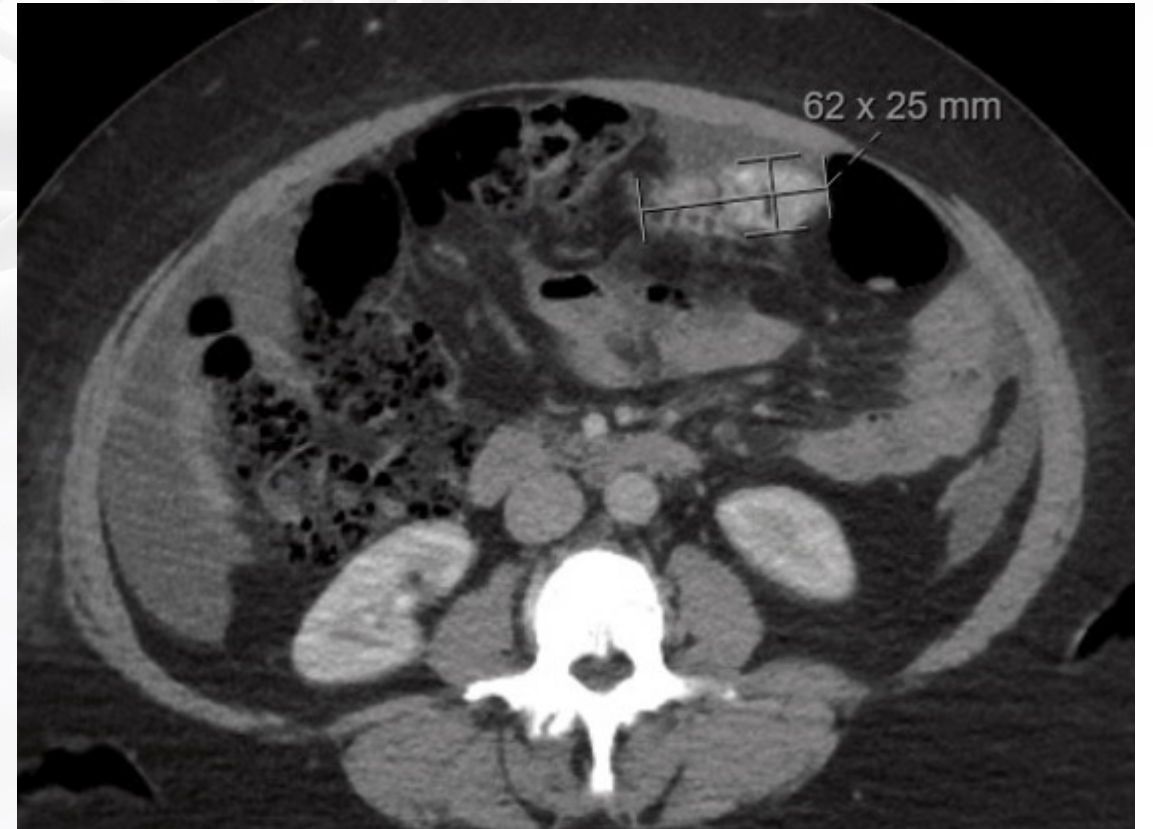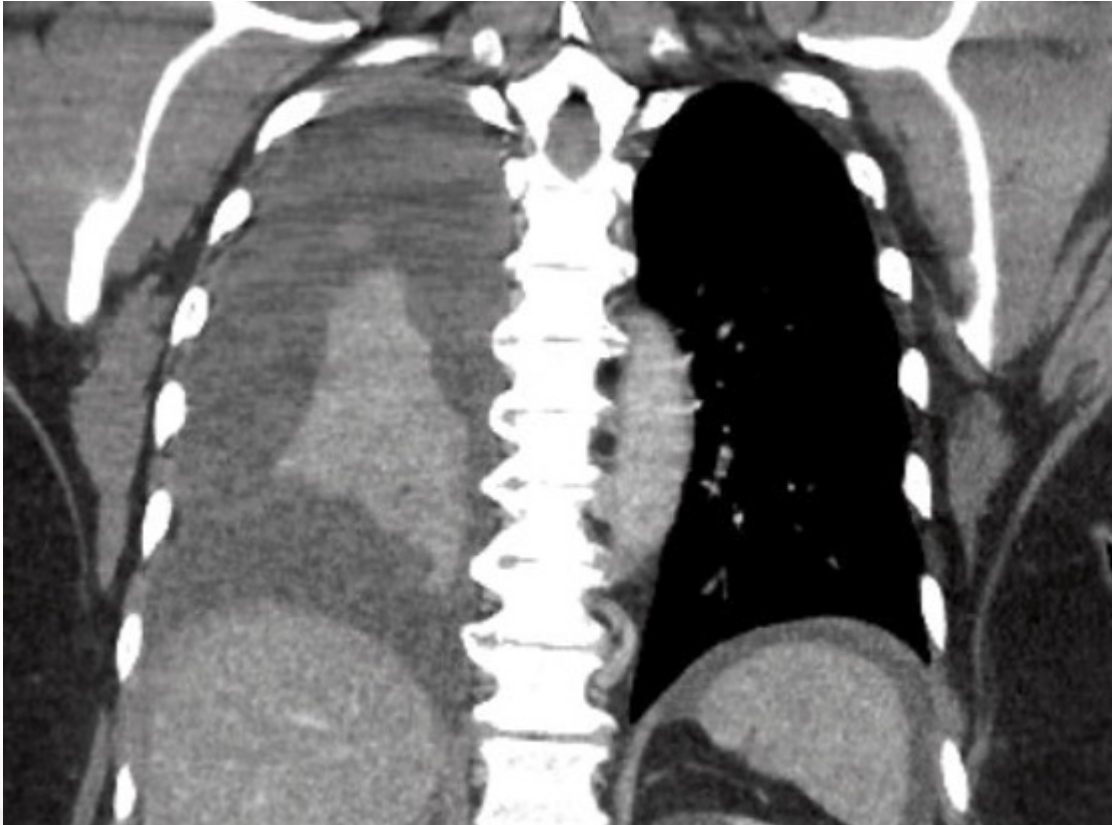
**Designated  
Comprehensive  
Cancer Center**

# Clinical Course

- 62F presented to the ED for SOB. Imaging with large right pleural effusion
- CA 125 1900
- Biopsy and cytology confirmed metastatic ovarian adenoCA
- Received 4C of NAC with carbo/taxol and underwent debulking surgery
- Completed 2C post-surgery with addition of bev. Continued Bev for maintenance
- Testing: BRCA and HRD negative, TMB 4 (low), MSS. Genetic testing negative



# Imaging



## Panel discussion

- How do you decide between carbo/taxol vs carbo/taxol/bev for NAC?
- What factors come into play when deciding NAC vs upfront optimal debulking?

## Clinical Course

- Surveillance scans around 5 months with progressive disease in the peritoneum
- Started on nab-paclitaxel
- Most recent scans with stable disease

## Panel discussion

- What are your thoughts on the addition of relacorilant to nab paclitaxel based on the ROSELLA trial? Will this become the new standard of care for platinum resistant ovarian cancer
- If testing was positive for BRCA, what are your thoughts on use of dostalimab and niraparib based on the First/ENGOT-OV44 trial, seems PFS was not clinically significant
- How would you sequence your treatment in platinum resistant ovarian cancer?