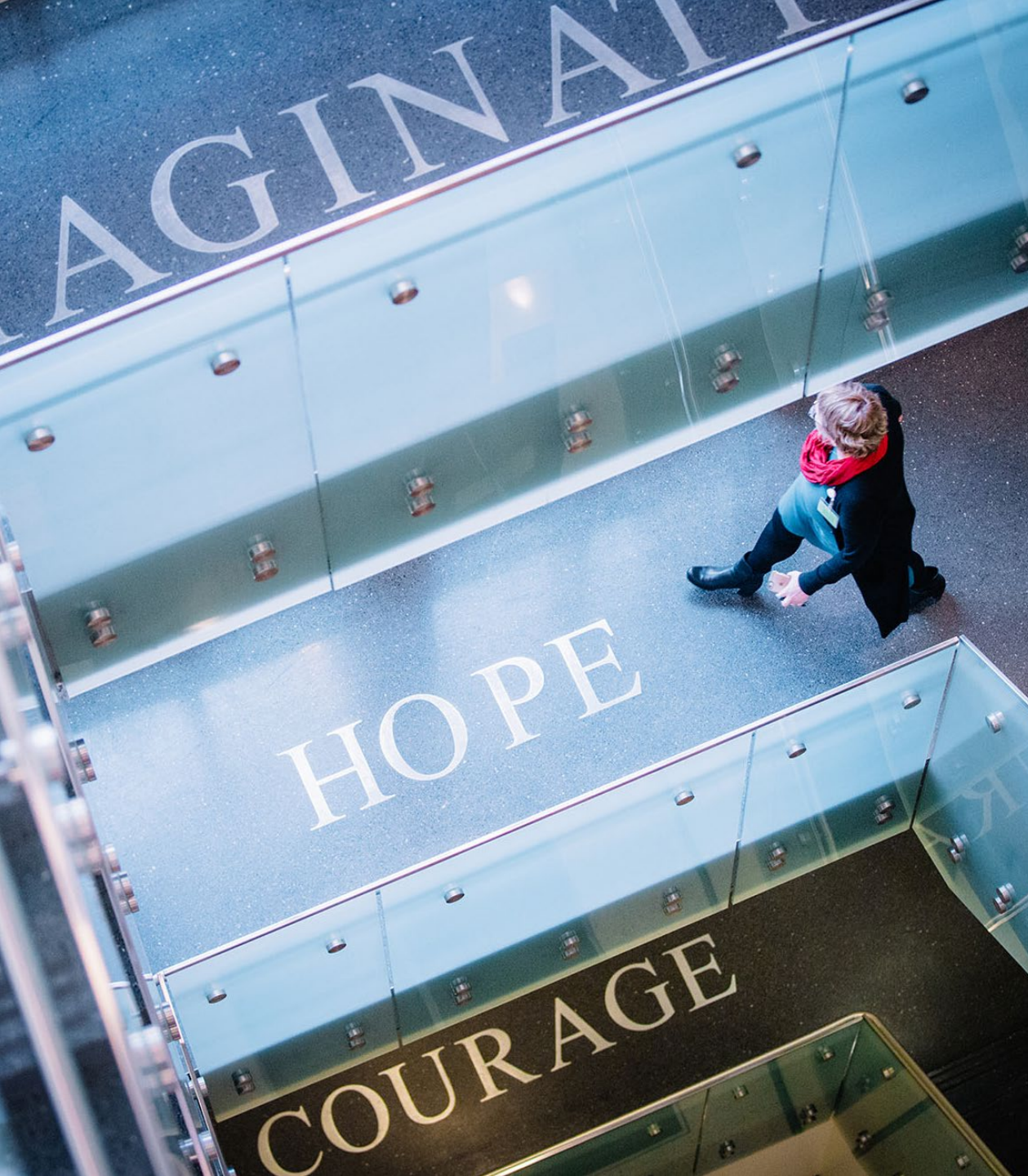




Patient-Based Panel Discussion CNS Malignancies

All Speakers: Drs. Kothari, Shoaf, Hoang

Case presented by Emory University Heme-Onc fellow:
Sarah J. Wood, MD

July 21st, 2023



Case Presentation

- Ms. ET is a 25 yo right-handed woman with right temporal G2 diffuse astrocytoma, IDH mt, low-level methylation, initially diagnosed in January 2020 after presenting with generalized tonic-clonic seizure to an outside hospital.
- She underwent craniotomy, with post-operative MRI demonstrating residual T2 FLAIR hyperintensity along the right subinsular region.
- Following surgery, she received proton radiation therapy: 54 Gy given in 30 fractions to the gross disease and resection cavity from 4/20/2020-6/1/2020. She completed treatment with expected toxicities including grade 1 alopecia, anorexia, radiation dermatitis, dry mouth, headache, nausea and tinnitus.
- MRI following radiation demonstrated post-treatment changes. She then completed 12 cycles of adjuvant temozolomide from July 2020 thru July 2021, and then transitioned to surveillance with MRI brain every 4 months with her local oncologist.

Case Presentation

- In 2023, she re-presented to EUH due to increased FLAIR on MRI brain located at the insula with close proximity to MCA vessels, suspicious for disease recurrence versus treatment-related changes.
- Further dedicated imaging 3D flair MRI with spectroscopy and perfusion are pending prior to determining next steps.



Panel discussion, Q&A

- In this case of low-grade astrocytoma, can you describe your approach for initial adjuvant treatment? Ms. ET was treated with radiation, followed by 12-months of Temozolomide. Would you have done the same?
- Given the proximity to large vessels in MCA, what would be your approach to obtaining repeat tissue biopsy?
- If disease recurrence is confirmed, what would second-line treatment options entail?

Vorasidenib in IDH1- or IDH2-Mutant Low-Grade Glioma

Ingo K. Mellinghoff, M.D., Martin J. van den Bent, M.D., Deborah T. Blumenthal, M.D., Mehdi Touat, M.D., Katherine B. Peters, M.D., Jennifer Clarke, M.D., M.P.H., Joe Mendez, M.D., Shlomit Yust-Katz, M.D., Liam Welsh, M.D., Ph.D., Warren P. Mason, M.D., François Ducray, M.D., Yoshie Umemura, M.D., [et al.](#)

